

Marian Fathy, Mohammed H El Agooz, Alahmady H Samman and Engy M Mostafa\*

Affiliation of authors: Ophthalmology Department, Sohag University, Sohag, Egypt

**Dates:** Received: 26 December, 2015; Accepted: 04 January, 2016; Published: 09 January, 2016

\*Corresponding author: Engy Mohamed Mostafa, MD, PhD, Ophthalmology Department, Sohag University, Nasr City, Sohag, 82524, Egypt, +2/01005643587; E-mail: engymostafa@yahoo.com

[www.peertechz.com](http://www.peertechz.com)

ISSN: 2455-1414

## Research Article

# Anterior Segment Characteristics of Keratoconus Eyes Using Scheimpflug-Placido Topography

### Abstract

**Purpose:** To assess anterior segment parameters of keratoconus (KC) eyes at different stages of the disease using Scheimpflug-placido topography (Sirius, CSO, Italy) in a sample of the southern Egyptian population.

**Methods:** retrospective study of 400 eyes of different grades of keratoconus along with 50 normal eyes as a control group were assessed for the following parameters: corneal thickness at apex (CCT), thinnest corneal thickness (TCT), anterior chamber depth (ACD), corneal volume (CV), corneal keratometry, corneal asphericity (Q), corneal elevation (both anterior and posterior) with aspherototic surface as a reference, total root mean square (RMS), RMS Coma, RMS spherical aberration (SA), RMS Astigmatism, Baiocchi Calossi Versaci front index (BCV<sub>f</sub>) and BCV back index (BCV<sub>b</sub>). They underwent Sirius Scheimpflug placid topographer evaluation.

**Results:** eyes were subdivided into: normal group (50 eyes), suspect KC (82 eyes), grade 1 KC (80 eyes), grade 2 KC (142 eyes), and grade 3 KC (96 eyes). The thinnest corneal thickness corneal thickness at apex and posterior corneal elevation were significantly different in all comparison groups. ACD values showed inconsistent differences between groups. Corneal volume was proved to be significant in comparing normal vs suspect KC group as well as in normal vs mild KC and normal vs moderate KC. Total RMS, RMS coma and BCV f and BCV b were significant for most groups

**Conclusion:** Corneal thickness and high order aberrations proved to be able to diagnose different grades of keratoconus while corneal volume did not prove to have a significant role.

## Introduction

The increasing volume of patients interested in refractive surgery and the new treatment options available for keratoconus have generated a higher interest in achieving a better characterization of this pathology [1]. Keratoconus is a bilateral non-inflammatory progressive disorder characterized by corneal ectasia and thinning [2-4]. Detecting moderate and advanced keratoconus is not difficult using corneal topography and biomicroscopic, retinoscopic, and pachymetric findings [3]. Several indices have been proposed to help in the diagnosis of keratoconus and subclinical keratoconus with different topography systems [5-13]. They include quantitative descriptors such as the KISA% index proposed by Rabinowitz and Rasheed [8], the Keratoconus Prediction Index and Keratoconus Index proposed by Maeda et al. [14]. Smolek and Klyce [7], developed a neural network classification based on corneal topography indices. Other detection schemes based on Zernike decomposition of the anterior corneal surface have been described by Schwiegerling et al. [15], and Langenbucher et al. [16]. With the Scheimpflug imaging system, corneal elevation either anterior or posterior started to be more investigated and researches debated which of the corneal surfaces had higher sensitivity in detecting keratoconus [11,17-20]. Incorporating corneal thickness, corneal volume and corneal curvature using a Scheimpflug camera have been evaluated in several other articles [21,22].

The Sirius system is a relatively new Scheimpflug-placido topographer that enables rapid acquisition and processing of the cornea and anterior chamber [23].

Our study was conducted to define changes in the anterior segment of keratoconus eyes at different stages of the disease in a sample of the southern Egyptian population with special emphasis on detecting parameters that can enable objective identification of early keratoconus.

## Patients and Methods

This study is a retrospective study of 500 patients (500 eyes) who were seeking refractive surgery in Sohag refractive center and diagnosed as clinical keratoconus between August 2014 and August 2015. In addition, fifty normal volunteer subjects (50 eyes) have been included as a control group. This study adhered to the tenets of the Declaration of Helsinki and was approved by the Ethics Committee, Sohag University Hospital, Egypt.

For analysis, keratoconus eyes have been classified into 4 subgroups according to Amsler-Krumeich classification [24]. The term keratoconus suspect was coined for corneal topography with abnormal localized steepening or an asymmetric bow-tie pattern, a normal-appearing cornea on slitlamp biomicroscopy, and at least 1 of the following signs: steep keratometric curvature (>47.00 D), oblique cylinder greater than 1.50 D, central corneal thickness less than 500 mm, or clinical keratoconus in the fellow eye [12,13,17,25,26].

Eyes were considered normal if they had no ocular pathology, no previous ocular surgery, no significant refractive error, and no irregular corneal pattern. In this group, only 1 eye of each patient was evaluated (random sampling).

Exclusion criteria were previous ocular surgery, corneal scarring, trauma, pregnancy or lactation, glaucoma and causes of ocular astigmatism other than corneal i.e. lenticular astigmatism such as early cataract, lens subluxation or lenticonus.

**Procedure**

All patients have been subjected to comprehensive eye examination and images were acquired by Scheimpflug placido topography (Sirius, Firenze, Italy) on all eyes with software version used 1.0.5.72 (Phoenix, Costruzione Strumenti Oftalmici). The scanning process acquires a series of 25 Scheimpflug images (meridians) and 1 Placido top view image. The ring edges are detected on the Placido image so that height, slope, and curvature data are calculated using the arc-step method with conic curves. From the Scheimpflug images, the profiles of anterior cornea, posterior cornea, anterior lens, and iris are derived. Anterior surface data from both Placido images and Scheimpflug images are merged using a proprietary method. All the other measurements for internal structures (posterior corneal curvature, anterior lens surface, and iris) are derived solely from Scheimpflug data. Previous studies have reported that the system’s pachymetric and shape measurements (curvature, eccentricity, elevation) have good repeatability [23,27]. Measurements were performed by a single experienced examiner (EM). Patient’s eye was aligned along the visual axis using a central fixation light. Patients were instructed to blink between shots to keep eyes moist. The examination which met excellent quality of the topographic and tomographic image, alignment and anterior and posterior coverage was saved. Eyes with scans not attainable, artificial tears were added to allow better acquisition.

In this study, the following parameters were evaluated: corneal thickness (CT) at the corneal apex, the thinnest corneal thickness (TCT), anterior chamber depth (ACD) defined as the distance from the corneal endothelium to the anterior surface of the lens capsule, corneal volume in a diameter of 9 mm, corneal volume (CV), keratometry (K) (both anterior and posterior as well as steep and flat keratometry), corneal asphericity (Q), corneal elevation (both anterior and posterior) with aspherotopic surface as a reference, total root mean square (RMS), RMS Coma, RMS spherical aberration (SA), RMS Astigmatism, Baiocchi Calossi Versaci front index (BCV<sub>f</sub>) and BCV back index (BCV<sub>b</sub>).

Schwiegerling et al. [5] and Li et al. [34], have shown that the following coefficients are the most relevant for keratoconus detection: vertical trefoil c3<sup>-3</sup>, vertical coma c3<sup>-1</sup>, horizontal coma c3<sup>+1</sup>, primary spherical aberration c4<sup>0</sup>, and second order vertical coma c5<sup>-1</sup>. The BCV<sub>f</sub> which is expressed in micrometers, was obtained by properly combining these coefficients (from the anterior corneal surface) and weighting them by a function of the coma axis. Likewise, a linear combination of c3<sup>-3</sup>, c3<sup>-1</sup>, c3<sup>+1</sup>, c4<sup>0</sup>, and c5<sup>-1</sup> and information about the coma axis on the posterior Zernike decomposition were used to define the BCV<sub>b</sub>.

**Statistical analysis**

Data was analyzed using STATA intercooled version 9.2. Quantitative data was analyzed using ANOVA and post hoc Bonferroni test for comparison of the means of the five groups. When the data was not normally distributed Kruskal – Wallis test and Mann-Whitney test was used. Correlation analysis was performed by using Pearson’s correlation test. Qualitative data was compared using Chi square test. Comparisons were made between all groups individually to try to deduct which factors were significant between groups G1 compared normal vs. suspect , G2 compared normal vs. mild KC, G3 compared normal vs. moderate KC, G4 compared normal vs. severe KC, G5 compared suspect vs. mild KC, G6 compared suspect vs. moderate KC, G7 compared suspect vs. severe KC, G8 compared mild KC vs. moderate KC , G9 compared mild KC vs. severe KC, G10 compared moderate KC vs. severe KC. P value was considered significant if it was ≤ 0.05.

**Results**

Demographic features of patients in normal eyes as control group along with the suspect KC and the other three groups of KC are stated in Table 1.

Table 2 and 3 shows anterior segment characteristics and corneal aberrations respectively. All parameters showed statistically significant differences between all groups (p<0.0001, one way ANOVA).

As expected the thinnest corneal thickness and corneal thickness at apex were significantly different in all comparison groups. Comparing suspect KC parameters against the mild KC parameters most of the values did not show any significance except for the anterior corneal power reading values (p=0.001).

Corneal volume was proved to be significant in comparing normal vs suspect KC group as well as in normal vs mild KC and normal vs moderate KC. Yet there was no correlation between steep keratometry and CV. ACD values showed inconsistent differences between groups. Posterior corneal elevation showed differences between all groups (Table 4).

Total RMS, RMS coma and BCV f and BCV b were significant for most groups except for the group 5 (Table 5).

Correlation of steep anterior keratometry showed significance with all parameters except corneal volume. Steep K revealed negative correlation with thinnest corneal point and thickness at apex which to be expected (Table 6).

There was strong positive correlation between anterior steep keratometry and all corneal aberrations (p=0.0001). The BCV parameter showed a positive correlation as well (Figure 1).

**Table 1:** Demographic features of patients.

Feature	Normal N=50	Suspect N=82	Mild KC N=80	Moderate KC N=142	Severe KC N=96
Age Mean ± SD (range)	26.7±6.0 (17-44)	27.4±9.3 (13-59)	28.9±10.7 (12-66)	26.2±9.5 (10-52)	23.6±7.7 (10-52)
Sex Male%	46%	52.4%	57.5%	48.6%	39.6%
Eye Rt/ Lt	29/21	42/40	45/35	70/72	44/52

**Table 2:** Anterior segment parameters and their comparisons between groups

Parameters Mean ± SD	Normal N=50	Suspect N=82	Mild KC N=80	Moderate KC N=142	Severe KC N=96
Thinnest location (um)	526.7±38.9	484.3±41.2	473.1±40.4	442.5±49.2	384.2±56.2
CT at apex (um)	579.1±63.0	529.4±55.2	507.1±60.5	472.9±52.6	422.1±68.9
ACD (mm)	3.1±0.3	3.2±0.4	3.2±0.4	3.3±0.3	3.6±0.4
Corneal volume (mm3)	56.6±3.9	52.3±4.0	53.6±4.0	53.9±4.1	55.2±4.7
Anterior mean K	42.2±1.1	42.5±1.3	45.0±1.19	47.2±1.9	55.5±6.1
Posterior mean K	-5.9±0.3	0.45±5.9	1.1±6.2	0.7±6.8	0.1±8.6
Anterior elevation	4±2.2	9±9.1	12±9.9	17±12.2	32±20
Posterior elevation	9.8±3.7	17.7±11.9	18.9±9.5	28.4±17.9	54.9±28.9

CT: Corneal Thickness, ACD: Anterior Chamber Depth, K: Keratometry

**Table 3:** Corneal aberrations parameters and their comparisons between groups.

Parameters Mean ± SD	Normal N=50	Suspect N=82	Mild KC N=80	Moderate KC N=142	Severe KC N=96
Corneal asphericity (Q)	0.2±0.1	0.3±0.3	0.5±0.4	0.9±0.6	1.7±0.8
Total RMS	0.4±0.2	0.5±0.4	0.7±0.6	1.2±0.7	3.4±2.5
RMS Spherical aberration	0.1±0.1	0.1±0.1	0.2±0.	0.2±0.2	0.7±0.7
RMS coma	0.2±0.1	0.3±0.2	0.5±0.6	0.9±0.7	2.2±1.5
RMS Astigmatism	-0.1±0.7	1.6±1.4	2.3±2.6	4.1±3.4	6.6±5.6
BCV f	0.2±0.2	0.8±0.8	1.1±.9	2.3±1.6	5.4±3.0
BCV b	0.1±0.2	0.9±0.8	1.3±1.3	2.5±1.7	5.0±3.2

RMS: Root Mean Square, BCV f: Baiocchi Calossi Versaci front index , BCV b: Baiocchi Calossi Versaci back index

**Table 4:** Multiple comparisons of anterior segment parameters between groups.

Parameters	G1	G2	G3	G4	G5	G6	G7	G8	G9	G10
ACD	0.84	0.34	0.006	<0.001	1.00	0.62	<0.0001	1.00	<0.0001	<0.0001
Thinnest location	<0.0001	<0.0001	<0.0001	<0.0001	1.00	<0.0001	<0.0001	<0.0001	<0.0001	<0.0001
CT at apex	<0.0001	<0.0001	<0.0001	<0.0001	0.18	<0.0001	<0.0001	<0.0001	<0.0001	<0.0001
Corneal volume	0.03	0.001	0.002	0.71	1.00	1.00	1.00	1.00	0.12	0.19
Ant. mean K	1.00	<0.0001	<0.0001	<0.0001	0.001	<0.0001	<0.0001	<0.0001	<0.0001	<0.0001
Post mean K	<0.0001	<0.0001	<0.0001	<0.0001	1.00	1.00	1.00	1.00	1.00	1.00
Ant. elevation	0.0001	0.0001	0.0001	0.0001	0.16	0.0001	0.0001	0.0001	0.0001	0.0001
Post. elevation	0.0001	0.0001	0.0001	0.0001	0.12	0.0001	0.0001	0.0001	0.0001	0.0001

CT: Corneal Thickness, ACD: Anterior Chamber Depth, K: Keratometry.

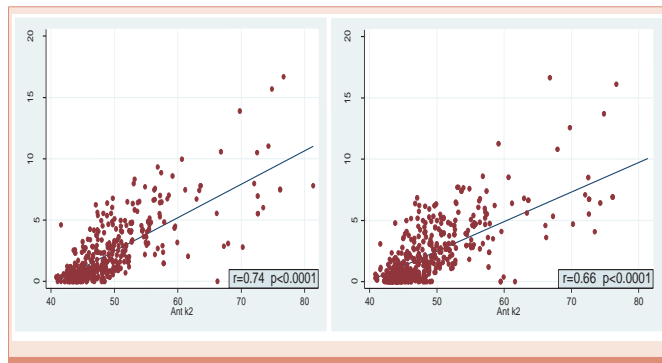
**Table 5:** Multiple comparisons of corneal aberrations parameters between groups.

Parameters	G1	G2	G3	G4	G5	G6	G7	G8	G9	G10
Total RMS	0.0007	0.0001	0.0001	0.0001	0.03	0.0001	0.0001	0.0001	0.0001	0.0001
Q	1.00	0.02	<0.0001	<0.0001	0.29	<0.0001	<0.0001	<0.0001	<0.0001	<0.0001
RMS SA	0.51	0.48	0.002	0.0001	0.15	0.01	0.0001	0.0003	0.0001	0.0001
RMS coma	0.0001	0.0001	0.0001	0.0001	0.009	0.0001	0.0001	0.0001	0.0001	0.0001
RMS Astigmatism	0.98	0.001	0.0001	0.0001	0.0001	0.0001	0.0001	0.0001	0.0001	0.0001
BCV f	0.0001	0.0001	0.0001	0.0001	0.06	0.0001	0.0001	0.0001	0.0001	0.0001
BCV b	0.0001	0.0001	0.0001	0.0001	0.20	0.0001	0.0001	0.0001	0.0001	0.0001

Q: Corneal Asphericity, RMS: Root Mean Square, BCV f: Baiocchi Calossi Versaci front index, BCV b: Baiocchi Calossi Versaci back index.

**Table 6:** Correlation between steep anterior keratometry and other parameters.

Parameters	Correlation co-efficient	P value
ACD (mm)	0.52	<0.0001*
Thinnest location (um)	-0.73	<0.0001*
CT at apex (um)	-0.59	<0.0001*
Corneal volume (mm2)	0.07	0.12
Anterior flat K	0.94	<0.0001*
Posterior flat K	0.04	0.38
Posterior steep K	0.02	0.69
Ant. elevation	0.33	0.05*
Post. elevation	0.71	<0.0001*



**Figure 1:** Correlation between anterior steep keratometry &  $BCV_p$  and  $BCV_b$ .

## Discussion

Detection of keratoconus is particularly important among patients considering refractive surgery in whom the presence of keratoconus and keratoconus suspect would yield unsatisfactory results and cause postoperative complications as corneal ectasia.<sup>28</sup> Difficulty recognizing keratoconus arises with very early or preclinical stages of the ectatic disorder [24,29-31].

The Scheimpflug placido imaging technology (Sirius) is a relatively new advancement that has been reported to be highly reproducible and repeatable [27,32,33]. To the best of our knowledge, this is the first study that investigated the characterization of anterior segment parameters of keratoconus eyes using the Scheimpflug-placido Sirius topographer in a Southern Egyptian population.

This study showed that several indices derived from Sirius measurements, including pachymetric readings and anterior and posterior corneal power along with corneal posterior elevation are helpful in discriminating eyes with different degrees of keratoconus from normal eyes. The TCT and posterior elevation seemed to be the best in discriminating suspect keratoconus eyes from normal eyes.

As corneal thinning is a key pathological feature of keratoconus; decrease of CCT and TCT is a distinguished sign of progression in the current study and can be used in monitoring the progression of the disease [20].

Schlegel et al. [12], used the Orbscan IIz slit-scanning topography on 60 normal myopic patients and 48 keratoconus suspect patients. They found that the differences between the keratoconus suspect group and normal group were statistically significant for thinnest pachymetries. In contrast, Rao et al. [34], did not find statistically significant differences in the mean central and thinnest point pachymetry values between keratoconus suspect patients and a control group. While Nilforoushan et al. [13], found that the suspect group had thinner pachymetry using the Pentacam.

In our study we found that the differences between the keratoconus group, suspect group and normal group were statistically significant in corneal thickness at apex and at thinnest location.

In the current study, the value of central ACD in normal group is slightly lower than those of Edmonds et al. [35], that used Scheimpflug photography ( $3.13 \pm 0.3$  versus  $3.18 \pm 0.32$  mm). Our results showed

progressively longer ACD values at center in mild, moderate and severe keratoconus subjects, with the highest values in the last group as in Abolbashari et al. study [36].

Corneal volume was recently investigated as an additive screening factor for keratoconus. In the present study the corneal volume measurements in eyes with mild to moderate keratoconus were significantly lower than those in a group of normal eyes which was similar to most reported studies [21,22,37,38]. In contrast Pinero et al. [22], reported inconsistent findings and that grade I KC did not show decrease in CV when compared to grade II KC. Yet in our study there was weak positive correlation between K and CV (0.07).

Gordon-Shaag et al. [39], reported that corneal higher order aberrations were found to be significantly higher for keratoconic than normal eyes, but for suspect keratoconus the results were mixed. Alio et al. [24], has established corneal aberrometry as a potential diagnostic tool for diagnosing keratoconus especially coma-like aberrations.

On the basis of previous studies showing that higher-order aberrations of the anterior corneal surface can be used as a tool to detect and grade keratoconus, we measured the front and back corneal surface root mean square of higher-order aberrations [24].

In our study corneal higher order aberrations were found to be higher for keratoconic than normal eyes as in Coma like aberration normal was  $0.2 \pm 0.1$   $\mu$ m, suspect was  $0.3 \pm 0.2$   $\mu$ m, mild was  $0.5 \pm 0.6$   $\mu$ m, moderate was  $0.9 \pm 0.7$   $\mu$ m and severe was  $2.2 \pm 1.5$   $\mu$ m but in spherical aberrations there was no difference between normal and suspect KC, mild and moderate KC but significantly higher in severe group of KC. Our study found also progressive increase in  $BCV_p$ ,  $BCV_b$  values (which are a combination of corneal high order aberrations) in suspect keratoconus and keratoconus subjects than normal corneas.

Several studies have addressed the topic of posterior corneal elevation and its relevance to early detection of keratoconus and that it is a useful index for discriminating this disease [17,34]. In the current study we found that posterior corneal elevation measured with the Sirius is higher in eyes with keratoconus or subclinical keratoconus than in normal corneas. As posterior elevation in normal was  $9.8 \pm 3.7$ , in suspect was  $17.7 \pm 11.9$ , in mild was  $18.9 \pm 9.5$ , in moderate was  $28.4 \pm 17.9$  and in severe was  $54.9 \pm 28.9$ .

In conclusion, Sirius is a valuable tool in diagnosing KC especially KC suspect and early KC.

## References

1. Pinero DP, Nieto JC, Lopez-Miguel A (2012) Characterization of corneal structure in keratoconus. *J Cataract Refract Surg* 38: 2167-2183.
2. Fontes BM, Ambrósio R Jr, Jardim D, Velarde GC, Nosé W (2010) Corneal biomechanical metrics and anterior segment parameters in mild keratoconus. *Ophthalmology* 117: 673-679.
3. Rabinowitz YS (1998) Keratoconus. *Surv Ophthalmol* 42: 297-319.
4. Wilson SE, Lin DT, Klyce SD (1991) Corneal topography of keratoconus. *Cornea* 10: 2-8.
5. Maeda N, Klyce SD, Smolek MK, Thompson HW (1994) Automated keratoconus screening with corneal topography analysis. *Invest Ophthalmol Vis Sci* 35: 2749-2757.

6. Rabinowitz YS (1995) Videokeratographic indices to aid in screening for keratoconus. *J Refract Surg* 11: 371-379.
7. Smolek MK, Klyce SD (1997) Current keratoconus detection methods compared with a neural network approach. *Invest Ophthalmol Vis Sci* 38: 2290-2299.
8. Rabinowitz YS, Rasheed K (1999) KISA% index: a quantitative videokeratography algorithm embodying minimal topographic criteria for diagnosing keratoconus. *J Cataract Refract Surg* 25: 1327-1335.
9. Auffarth GU, Wang L, Volcker HE (2000) Keratoconus evaluation using the Orbscan Topography System. *J Cataract Refract Surg* 26: 222-228.
10. Pflugfelder SC, Liu Z, Feuer W, Verm A (2002) Corneal thickness indices discriminate between keratoconus and contact lens-induced corneal thinning. *Ophthalmology* 109: 2336-2341.
11. Fam HB, Lim KL (2006) Corneal elevation indices in normal and keratoconic eyes. *J Cataract Refract Surg* 32: 1281-1287.
12. Schlegel Z, Hoang-Xuan T, Gatinel D (2008) Comparison of and correlation between anterior and posterior corneal elevation maps in normal eyes and keratoconus-suspect eyes. *J Cataract Refract Surg* 34: 789-795.
13. Nilforoushan MR, Speaker M, Marmor M, Abramson J, Tullo W, et al. (2008) Comparative evaluation of refractive surgery candidates with Placido topography, Orbscan II, Pentacam, and wavefront analysis. *J Cataract Refract Surg* 34: 623-631.
14. Maeda N, Klyce SD, Smolek MK (1995) Neural network classification of corneal topography. Preliminary demonstration. *Invest Ophthalmol Vis Sci* 36: 1327-1335.
15. Schwiegerling J, Greivenkamp JE (1996) Keratoconus detection based on videokeratoscopic height data. *Optom Vis Sci* 73: 721-728.
16. Langenbucher A, Gusek-Schneider GC, Kus MM, Huber D, Seitz B (1999) [Keratoconus screening with wave-front parameters based on topography height data]. *Klin Monbl Augenheilkd* 214: 217-223.
17. de Sanctis U, Loiacono C, Richiardi L, Turco D, Mutani B, et al. (2008) Sensitivity and specificity of posterior corneal elevation measured by Pentacam in discriminating keratoconus/subclinical keratoconus. *Ophthalmology* 115: 1534-1539.
18. Tomidokoro A1, Oshika T, Amano S, Higaki S, Maeda N, et al. (2000) Changes in anterior and posterior corneal curvatures in keratoconus. *Ophthalmology* 107: 1328-1332.
19. Bessho K, Maeda N, Kuroda T, Fujikado T, Tano Y, et al. (2006) Automated keratoconus detection using height data of anterior and posterior corneal surfaces. *Jpn J Ophthalmol* 50: 409-416.
20. Ucakhan OO, Cetinkor V, Ozkan M, Kanpolat A (2011) Evaluation of Scheimpflug imaging parameters in subclinical keratoconus, keratoconus, and normal eyes. *J Cataract Refract Surg* 37: 1116-1124.
21. Ambrosio R, Jr., Alonso RS, Luz A, Coca Velarde LG (2006) Corneal-thickness spatial profile and corneal-volume distribution: tomographic indices to detect keratoconus. *J Cataract Refract Surg* 32: 1851-1859.
22. Piñero DP, Alió JL, Alesón A, Escaf Vergara M, Miranda M (2010) Corneal volume, pachymetry, and correlation of anterior and posterior corneal shape in subclinical and different stages of clinical keratoconus. *J Cataract Refract Surg* 36: 814-825.
23. Milla M, Pinero DP, Amparo F, Alio JL (2011) Pachymetric measurements with a new Scheimpflug photography-based system: intraobserver repeatability and agreement with optical coherence tomography pachymetry. *J Cataract Refract Surg* 37: 310-316.
24. Alio JL, Shabayek MH (2006) Corneal higher order aberrations: a method to grade keratoconus. *J Refract Surg* 22: 539-545.
25. Jafri B, Li X, Yang H, Rabinowitz YS (2007) Higher order wavefront aberrations and topography in early and suspected keratoconus. *J Refract Surg* 23: 774-781.
26. Lim L, Wei RH, Chan WK, Tan DT (2007) Evaluation of higher order ocular aberrations in patients with keratoconus. *J Refract Surg* 23: 825-828.
27. Masoud M, Livny E, Bahar I (2015) Repeatability and intrasession reproducibility obtained by the Sirius anterior segment analysis system. *Eye Contact Lens* 41: 107-110.
28. Randleman JB, Russell B, Ward MA, Thompson KP, Stulting RD (2003) Risk factors and prognosis for corneal ectasia after LASIK. *Ophthalmology* 110: 267-275.
29. Piñero DP, Alió JL, Alesón A, Escaf M, Miranda M (2009) Pentacam posterior and anterior corneal aberrations in normal and keratoconic eyes. *Clin Exp Optom* 92: 297-303.
30. Gobbe M, Guillon M (2005) Corneal wavefront aberration measurements to detect keratoconus patients. *Cont Lens Anterior Eye* 28: 57-66.
31. Accardo PA, Pensiero S (2002) Neural network-based system for early keratoconus detection from corneal topography. *J Biomed Inform* 35: 151-159.
32. Nasser CK, Singer R, Barkana Y, Zadok D, Avni I, et al. (2012) Repeatability of the Sirius imaging system and agreement with the Pentacam HR. *J Refract Surg* 28: 493-497.
33. De la Parra-Colin P, Garza-Leon M, Barrientos-Gutierrez T (2014) Repeatability and comparability of anterior segment biometry obtained by the Sirius and the Pentacam analyzers. *Int Ophthalmol* 34: 27-33.
34. Rao SN, Raviv T, Majmudar PA, Epstein RJ (2002) Role of Orbscan II in screening keratoconus suspects before refractive corneal surgery. *Ophthalmology* 109: 1642-1646.
35. Edmonds CR, Wung SF, Pemberton B, Surrent S (2009) Comparison of anterior chamber depth of normal and keratoconus eyes using Scheimpflug photography. *Eye Contact Lens* 35: 120-122.
36. Abolbashari F, Mohidin N, Ahmadi Hosseini SM, Mohd Ali B, Retnasabapathy S (2013) Anterior segment characteristics of keratoconus eyes in a sample of Asian population. *Cont Lens Anterior Eye* 36: 191-195.
37. Mannion LS, Tromans C, O'Donnell C (2011) Reduction in corneal volume with severity of keratoconus. *Curr Eye Res* 36: 522-527.
38. Emre S, Doganay S, Yologlu S (2007) Evaluation of anterior segment parameters in keratoconic eyes measured with the Pentacam system. *J Cataract Refract Surg* 33: 1708-1712.
39. Gordon-Shaag A, Millodot M, Iffrah R, Shneor E (2012) Aberrations and topography in normal, keratoconus-suspect, and keratoconic eyes. *Optom Vis Sci* 89: 411-418.

**Copyright:** © 2016 Fathy M, et al. This is an open-access article distributed under the terms of the Creative Commons Attribution License, which permits unrestricted use, distribution, and reproduction in any medium, provided the original author and source are credited.

**Citation:** Fathy M, El Agooz MH, Samman AH, Mostafa EM (2016) Anterior Segment Characteristics of Keratoconus Eyes Using Scheimpflug-Placido Topography. *J Clin Res Ophthalmol* 3: 003-007. DOI: 10.17352/2455-1414.000027